European Journal of Radiology 84 (2015) 431–436

Contents lists available at ScienceDirect

European Journal of Radiology

journal homepage: www.elsevier.com/locate/ejrad

MR imaging of transient osteoporosis of the hip: An update on 155 hip joints

Michail E. Klontzas[a], Evangelia E. Vassalou[a], Aristeidis H. Zibis[b], Antonia S. Bintoudi[c], Apostolos H. Karantanas[a,*]

[a] Department of Medical Imaging, University Hospital of Heraklion, Medical School, University of Crete, Greece
[b] Department of Anatomy, University of Thessalia, Medical School, Larissa, Greece
[c] Department of Radiology, "Papageorgiou" General Hospital of Thessaloniki, Greece

ARTICLE INFO

Article history:
Received 29 August 2014
Received in revised form 1 November 2014
Accepted 12 November 2014

Keywords:
Transient osteoporosis
Hip
Bone marrow edema
Regional migratory osteoporosis

ABSTRACT

Purpose: Transient osteoporosis of the hip (TOH) presents with acute onset pain and bone marrow edema (BMe) on MR imaging. The purpose of this study is to revise the MR imaging characteristics of TOH by analyzing the data derived from 155 hip examinations. We also sought to explore the relationship between the duration of symptoms and the presence of sparing and subchondral fractures.
Materials and methods: MR images of 155 hips (141 TOH patients) were retrospectively evaluated for the presence of insufficiency fractures and the morphology of BMe. Sparing of the medial bone marrow of the femoral head was recorded together with demographic and clinical data. Progression to regional migratory osteoporosis (RMO) and postpartum cases were also recorded.
Results: Our population consisted of 76.4% male and 23.6% female patients. RMO progression was recorded in 19.4% and 4 postpartum cases displayed bilateral disease. Sparing of the medial bone marrow was present at 87.7% of patients and disappeared as the disease progressed ($P = 0.005$). BMe was restricted within the femoral head in 11.0%, extended to the femoral neck in 40% and to the femoral shaft in 49% of the cases studied. Subchondral fractures were present at 48.7% of the hips.
Conclusion: This study describes TOH patient characteristics, the MR imaging findings (BMe pattern, microfractures), their association with symptom duration and the chance of progressing to RMO.

1. Introduction

Bone marrow edema (BMe) of the proximal femur is a non-specific MR imaging finding associated with a wide variety of disorders. BMe can be classified into two broad categories: reversible with conservative treatment, such as transient osteoporosis of the hip (TOH), regional migratory osteoporosis (RMO), chronic regional pain syndrome (CRPS), trauma – including stress injuries and insufficiency fractures – and non-reversible, such as avascular necrosis (AVN), infection, tumors, and degenerative and inflammatory arthropathy [1–7].

Reversible clinical entities such as TOH, RMO and CRPS are widely known as acute BME syndromes (aBMEs) [8] which have in common the presence of BMe and their history of acute onset without trauma. However, extensive literature discussion still exists on the differential diagnosis between aBMEs and AVN [9,10]. The differentiation between the two entities is important in terms of treatment and prognosis, as aBMEs are self-limiting and resolve with conservative treatment (e.g. restriction of weight bearing, anti-resorptive drugs and analgesics), whereas AVN is progressive and may require surgical intervention. In this respect, MR imaging is extremely helpful in the differential diagnosis and guidance of further treatment strategies.

The purpose of our study is to provide an update on the MR imaging findings of TOH by presenting the largest series of TOH patients to date. Namely, we sought (1) to provide an update on the characteristics of TOH patients, (2) to analyze the pattern of BMe and the prevalence of subchondral fractures and assess their relation to the duration of symptoms up to the first MR imaging examination, (3) to evaluate the chance of progression of TOH to RMO.

* Corresponding author at: Department of Medical Imaging, University Hospital, Voutes 71110, Heraklion – Crete, Greece. Tel.: +30 2813392541; fax: +30 2813542095.
E-mail addresses: akarantanas@gmail.com, karantanas@med.uoc.gr (A.H. Karantanas).

http://dx.doi.org/10.1016/j.ejrad.2014.11.022
0720-048X/

2. Materials and methods

2.1. Patients

Our study has been conducted under the principles of Helsinki's Declaration, our hospital's ethics committee has approved the retrospective use of anonymized imaging data for research purposes and all patients have signed an informed consent. Our center is the only one in the country with a special interest on the imaging of non-neoplastic bone marrow disorders, receiving thus referrals for suspected TOH cases.

MR imaging examinations of all consecutive TOH cases initially presenting or referred to our department from August 2004 to July 2014, were retrospectively reviewed. Our study population consists of 155 hip joints from 141 patients, who were included in the study. The inclusion criteria consist of (a) a history of acute onset of hip pain extending to the groin and/or the thigh, in the absence of trauma and (b) confirmation of TOH in all cases by MR imaging and follow-up data, including spontaneous resolution of symptoms and/or BMe, only with conservative treatment. Our exclusion criteria were the history of insidious onset of pain, together with the presence of AVN, infection, tumors, trauma, insufficiency fractures and inflammatory arthropathy, as confirmed by means of MR imaging and laboratory examinations.

Data on the duration of pain till their first MR imaging examinations was available for 114 of the 141 patients. The majority of our patients' files included a plain hip radiograph and for 31 patients a DEXA scan of the lumbar spine was also available. Follow-up data ranged between 1 and 10 years depending on the time of clinical improvement, with the exclusion of three patients who had a recent diagnosis. In patients with recurrent symptoms in another joint, follow up MR imaging examination was available.

2.2. Measurements

The age, sex and the side affected were recorded for all patients. BMe sparing of the medial bone marrow of the femoral head and the presence of subchondral insufficiency fractures (deep subcortical low-signal lines surrounded by the high-signal edematous bone marrow on fluid sensitive images) were also recorded. Moreover, the degree of BMe extension was assessed and classified into three categories: (a) location within the femoral head, (b) extending to the femoral neck, (c) extending distally from the femoral neck to the proximal femoral shaft. Extension of BMe to the area of the greater trochanter was assessed as well.

All MR imaging examinations were retrospectively blindly reviewed by two evaluators (a senior radiology resident and a research fellow) and in cases of conflict, the examinations were blindly reviewed by the senior author (a musculoskeletal radiologist with 27 years of experience on bone marrow disorders).

2.3. MR imaging

MR imaging examinations of our study population have been obtained in various 1.5 and 3 T MR Scanners, as our department serves as a reference center for the imaging of bone marrow disorders. In cases that the examinations provided by the referring center were technically poor, they were repeated in our institution's 1.5 MR imager (Vision/Sonata, Siemens, Erlangen).

For the purposes of our study, the following sequences were evaluated: coronal T1 turbo inversion recovery (STIR), coronal T1-w, axial fat suppressed PD/T2-w, oblique fat suppressed small field of view PD-w and when available fat suppressed contrast enhanced T1-w images in various planes.

2.4. Statistical analysis

For the purposes of our statistical analysis, MedCalc 12.7.1 statistical software (MedCalc Software, Belgium) was used. Mann–Whitney *U* test was used to compare the duration of symptoms between patients with medial marrow sparing and those without sparing, as well as between people with and without subchondral fractures. In order to calculate the inter-observer agreement on the presence of spared bone marrow and insufficiency fractures, kappa coefficient was calculated on 21 randomly chosen hip examinations.

3. Results

3.1. Study population characteristics

Our study population consisted of 107 male (76.4%) and 34 female (23.6%) patients with a mean age of 45.5 ± 9.8 years. There were 4 (2.9%) patients with postpartum BMe all of whom had bilaterally involvement. Between non-postpartum cases, only 4 out of 137 patients (2.9%) presented with both hips affected simultaneously. Out of 155 hips, 83 (53.5%) were left and 72 (46.5%) were right. The youngest patient was a male 23-year-old and the oldest a male 73-year-old.

Progression to RMO occurred to 19.4% of the affected hips (30 out of 155 hips) with a median time to progression of 12.0 months (mean time 26.7, 95% CI from 10 to 43.2). No cases were found to progress to AVN.

Fifteen out of 31 patients (18 males, 13 females) with available DEXA examinations at the lumbar spine, showed osteopenia, 15 osteoporosis and one was normal (Table 1). The mean age of the patients, presenting with osteopenia or osteoporosis, who were evaluated with DEXA, was 47.5 years.

3.2. Pattern of BMe

All MR imaging examinations showed BMe, which was demonstrated as a high signal intensity area on fluid sensitive sequences. One hundred and thirty six out of 155 hips (87.7%) displayed sparing of the medial bone marrow of the femoral head, whereas subchondral fractures were present at 76/155 (48.7%) (Figs. 1–4).

The mean duration of symptoms before the first MR imaging examination was 4.5 weeks (95% CI from 3.85 to 5.14 weeks). Statistical analysis proved a statistically significant association between the duration of symptoms and the presence of sparing, with a mean duration of 4.3 weeks (95% CI from 3.63 to 4.94) for cases with sparing, compared to 6.8 weeks for cases where BMe had totally occupied the femoral head ($P = 0.005$) (Figs. 2 and 5). However, there was no statistically significant association between the duration of symptoms and the presence of subchondral fractures ($P = 0.419$).

In 17 (11.0%) out of 155 hips BMe was restricted to the femoral head, in 62 (40%) BMe was present also in the femoral neck and in 76 (49%) hips BMe was extending distally to the proximal shaft of the femur (Figs. 2–5). Interestingly, the bone marrow of the greater trochanter was affected only in 6 hips (3.9%) (Figs. 3 and 4).

Inter-rater agreement was high for both the presence of bone marrow sparing by BMe and the presence of subchondral fractures, with a kappa coefficient for sparing of 1.0 (95% CI from 1.0 to 1.0) and for fractures of 0.8 (95% CI from 0.54 to 1.0).

4. Discussion

After the initial description of TOH at 1959 [11], only limited reports on series of cases exist, with the largest being that of Malizos et al. [3], with 42 patients. We hereby attempt to introduce a more

Table 1
Characteristics of patients with an available DEXA of the lumbar spine.

Patient no.	Age	Sex (M/F)	DEXA *T*-score	Sparing (+/−)	BMe extension[a]
1	45	M	−0.8	+	2
2	26	F	−1.4	+	3
3	34	F	−1.8	+	3
4	30	M	−1.4	+	3
5	36	M	−1.9	−	3
6	25	F	−1.2	+	2
7	33	M	−1.4	−	3
8	28	F	−1.5	+	3
9	35	M	−1.6	−	3
10	55	F	−2	+	3
11[b]	46	M	−2.2	−	N/A
12[b]	49	M	−2.1	−	N/A
13	48	F	−1.9	+	2
14[b]	43	M	−1.8	+	3
15[b]	37	M	−2.3	+	3
16	36	F	−2.4	+	3
17	48	F	−2.5	+	2
18[b]	62	M	−3.3	+	3
19	45	F	−2.8	+	2
20	59	F	−2.9	+	3
21	67	M	−3.5	+	3
22	57	F	−2.6	+	2
23	54	M	−2.9	+	3
24	66	F	−2.6	+	1
25[b]	57	M	−2.7	+	3
26[b]	60	M	−2.8	+	2
27	73	M	−3.4	+	3
28	63	F	−2.7	+	3
29[b]	52	M	−3.2	+	3
30[b]	35	M	−3.3	+	2
31	70	M	−2.6	+	3

A *T*-score of greater than −1 is considered normal. A *T*-score of −1 to −2.5 is considered osteopenia, and a risk factor for developing osteoporosis. A *T*-score of less than −2.5 is diagnostic of osteoporosis.

[a] Bone marrow edema (BMe) was classified as follows: (1) for cases where it was restricted to the femoral head, (2) for cases where it extended up to the intertrochanteric region (3) for cases where it extended to the femoral shaft.

[b] Cases with regional migratory osteoporosis.

N/A: non-applicable due to insufficient field of coverage.

accurate and detailed description of this clinical entity and its MR imaging appearance.

Several case reports and patient series describe TOH as a disease mostly affecting patients during the fourth decade of their life [2,3,12,13], with a male predominance and a predilection for left hips. Our results confirm the above data with an approximately 3:1 male:female ratio. Moreover, our study comes to confirm findings described in case reports regarding postpartum cases [14]. In fact all of our postpartum cases were bilateral. However, we do not report any noticeable difference between the proportion of left and right hips.

It is nowadays accepted that RMO constitutes a progression of TOH [13,15,16] with studies proposing a common pathophysiology between the two entities [17]. Cahir et al. [15] have proposed that 72% of TOH patients progress to RMO during the first year after their diagnosis. However, only 19.4% of our TOH patients progressed to RMO. This information is of great importance informing both clinicians and patients that there is a chance of about one out of five for additional involvement in the future.

Although the pathophysiology of TOH has not yet been clarified, it is now clear that it has no relationship with AVN, which was originally thought to be a later stage of TOH [2,9,10]. As a result, the differentiation between them is extremely important as it can protect TOH patients from invasive procedures. The difference between the two entities is also highlighted by our study, where none of our 155 hips progressed to AVN. Moreover, it has to be pointed out that although BMe is present at later stages of AVN complicated with articular collapse, the appearance of necrosis is unique on MR imaging [18] and should not be confused with the microtrabecular insufficiency subchondral fractures found in TOH

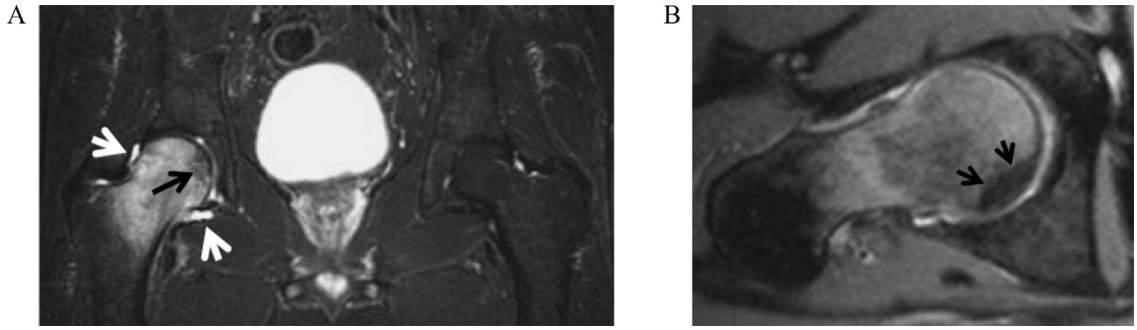

Fig. 1. A 51-year-old male patient with a history of 1 week pain prior to the MR imaging examination. The coronal STIR MR image (A) and the oblique axial fat suppressed PD-w MR image (B), show sparing of the medial femoral head bone marrow (black arrows) and joint effusion (white arrows).

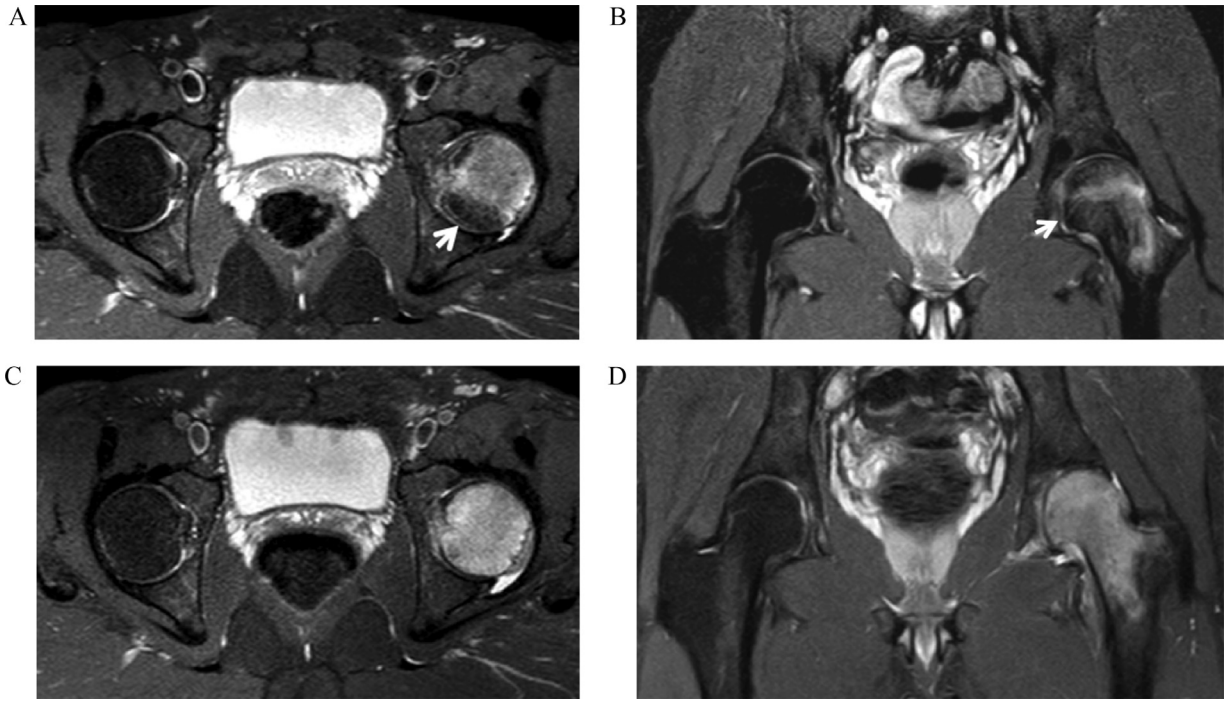

Fig. 2. A 30-year-old male with vitamin D deficiency and osteopenia on DEXA of the lumbar spine. The axial fat suppressed PD-w (A) and coronal STIR (B) images obtained 2 weeks after the onset of pain show medial bone marrow sparing (white arrow) and extension of bone marrow edema to the femoral shaft. Follow-up images (C and D) obtained 3 weeks later at the peak of pain intensity, show occupation of the spared bone marrow area by edema and extension to the greater trochanter.

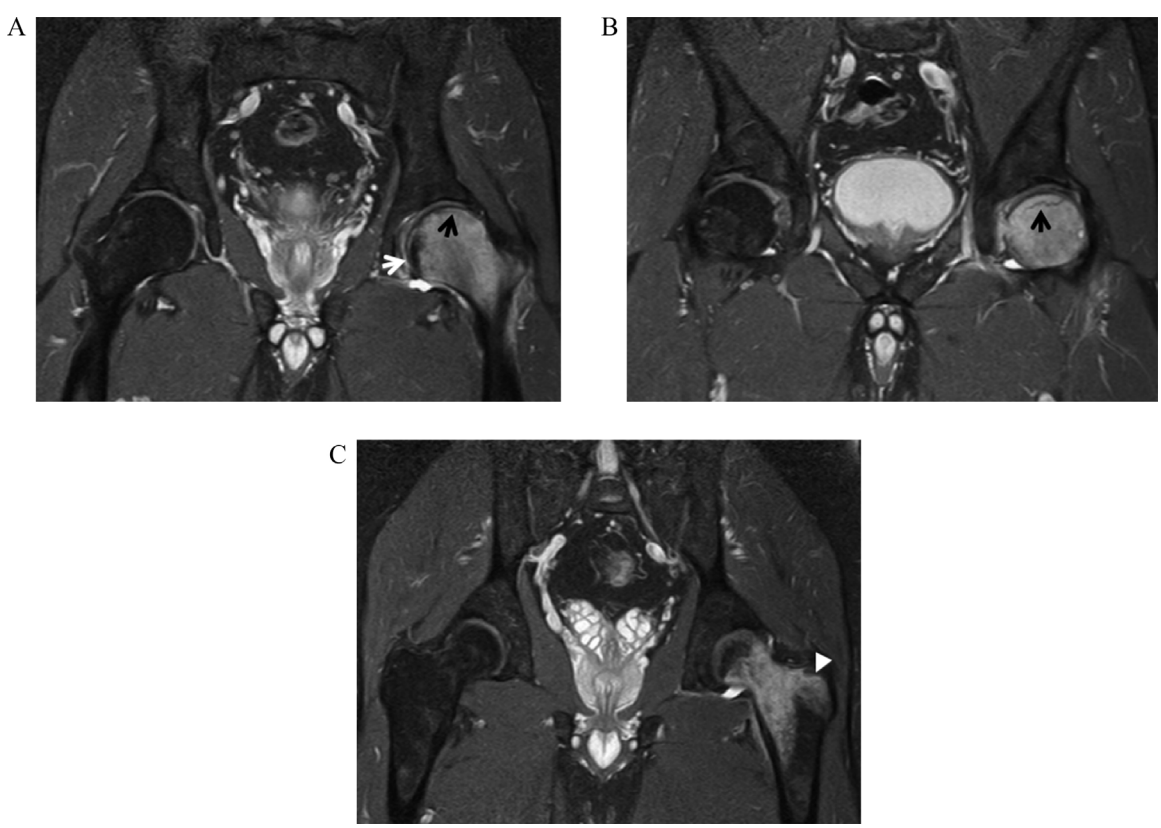

Fig. 3. A 43-year-old male patient with a history of 1 month left hip pain. (A) and (B) The coronal STIR images show sparing of the medial bone marrow (white arrow). A subchondral fracture is also nicely demonstrated (black arrows). (C) The coronal STIR image shows extension of bone marrow edema to the greater trochanter (arrowhead).

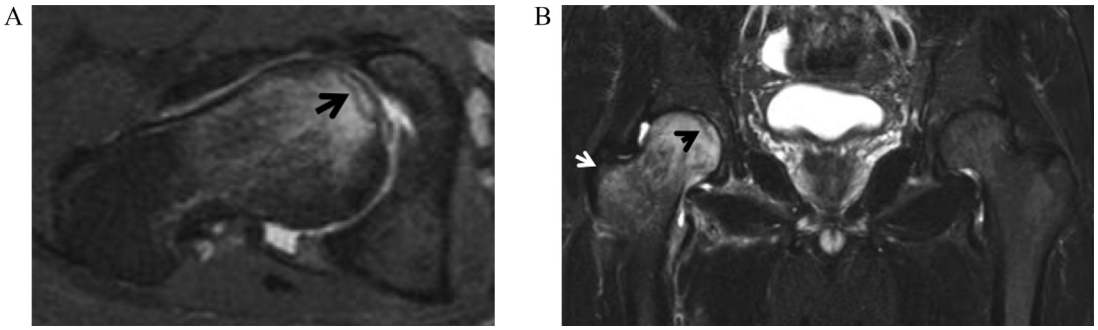

Fig. 4. MR images of two patients with subchondral fractures. (A) A 26-year-old male. The oblique axial fat suppressed PD-w MR image shows the low signal intensity subchondral line representing the microtrabecular fracture (arrow), surrounded by moderate bone marrow edema. (B) A 46-year-old male. The coronal STIR image shows the subchondral fracture (black arrow) and the extension of bone marrow edema to the greater trochanter (white arrow).

patients. This comes to contrast the results of Trevisan et al. [17] who propose a common pathophysiology between TOH, RMO and AVN but is in line with the results of Malizos et al. [3].

The prevalence of insufficiency fractures has been reported by Malizos et al. [3] to be about 4%. In our study such sub-chondral changes were present at almost half of our study group. This difference could most possibly be attributed to the low-resolution 1T images of the previous study that could have led to an underestimation of these lesions. The high prevalence of the subchondral changes comes to contrast the original belief that their presence might not be associated with benign and self-limiting disorders such as TOH. Moreover, in contrast to the study by Vande Berg et al. [19], the low signal intensity subchondral areas in the present study, were not associated with a poor outcome regardless of their size, as all our patients recovered completely with conservative treatment.

We have noticed that BMe of the femoral head spared the inferomedial part of the femoral head in 87.7% of our patients. This can be possibly explained by the arrangement of the supporting trabeculae inside the femoral head. Their microscopic architecture along with the patients' age, which is consistent with robust trabeculae, may leave this portion of the femoral head intact in terms of BMe diffusion (Fig. 6). We have also showed that there is a relationship between the duration of symptoms and the presence of bone marrow sparing. This could be attributed to the expansion of BMe over time and the inability of the supporting trabeculae to contain the edema (Figs. 2 and 5). Thus, this finding could be used as an additional indicator of the severity of disease and the expecting date of resolution of symptoms. The "sparing" sign was originally reported to occur in between 14 and 17th weeks after onset [4]. This difference in findings between the two studies may be explained on the basis of larger group of patients in the current report.

Our study, to the best of our knowledge, is the first to present a significant number of DEXA scans in TOH patients. All of them report a decreased bone density (either osteopenia or osteoporosis) as measured at the lumbar spine. This could possibly serve as

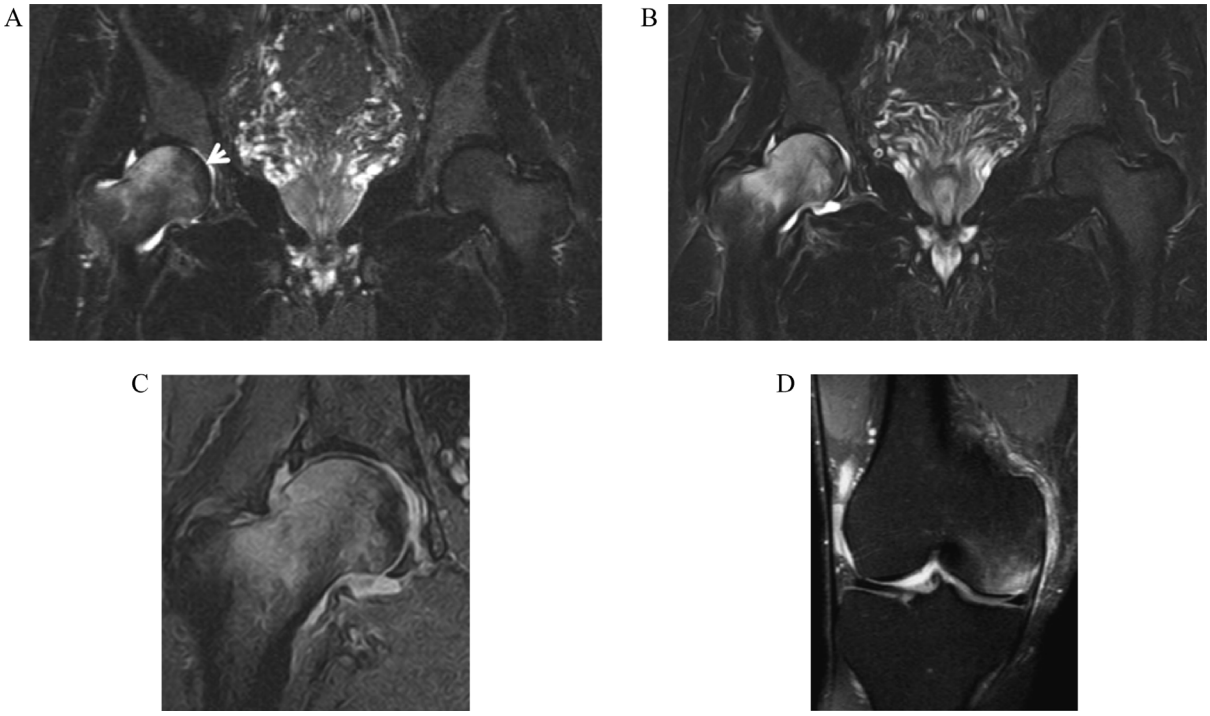

Fig. 5. A 57-year-old male patient with right hip joint pain and a diagnosis of regional migratory osteoporosis syndrome. The coronal STIR MR image (A) obtained at 13/3/13 shows mild bone marrow edema and medial bone marrow sparing (white arrow). Follow-up MR imaging examination was obtained at 10/4/13 with the patient reporting symptom deterioration. The coronal STIR (B) and high resolution fat suppressed PD-w images (C), show expansion of the bone marrow edema and reduction of the bone marrow sparing. At November 2012 prior to the hip MR imaging studies, the patient reported knee pain and the coronal STIR image (D) showed medial femoral condyle bone marrow edema.

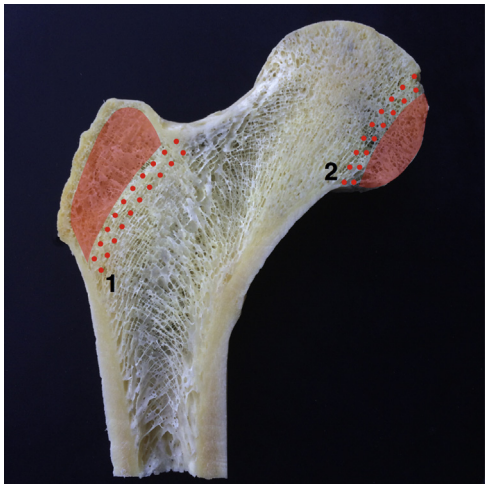

Fig. 6. Middle coronal section of a dry bone specimen from a 50-year-old male displaying the microscopic anatomy of the micro-trabecular network. Principal tensile (1) and principal compressive trabeculae (2) form regions of the proximal femur where bone marrow edema does not extend in the beginning of the disease process (shaded red) resulting thus to the "sparing" sign.

a pathophysiologic explanation of TOH, with osteoporosis being the cause of microtrabecular fractures resulting to BMe. This is further enhanced by the fact that pregnancy may be associated with reduced bone mass and all the postpartum cases showed involvement of both hips. However, further research is needed in order to examine this hypothesis.

The major strength of our study is the size of our patient's group, which enables safer estimations of frequencies and thus a most accurate description of TOH. Moreover the inclusion of RMO cases provides a global description of a spectrum of diseases closely related to each other, providing valuable information to patients i.e. the chance of progressing to RMO. The present study has a number of limitations: (1) The variety of MR scanners used for the study, which was inevitable as we serve as a reference center for bone marrow disorders and many of the referred patients had already undergone an MR imaging examination before seeking consultation; (2) the retrospective nature of the study; (3) the lack of clinical data in a number of patients and (4) the possibility of underestimating the rate of progression to RMO as there might be patients who did not seek second consultation in our department.

In conclusion, this study describes the characteristics of TOH. It provides an estimation of the chance of RMO progression and describes the pattern of BMe with respect to the duration of symptoms. In addition, our study demonstrates the high prevalence of subchondral microfractures present in TOH patients, which are never complicated with AVN or articular collapse.

Conflict of interest

No conflict of interest to disclose.

References

[1] Korompilias AV, Karantanas AH, Lykissas MG, Beris AE. Transient osteoporosis. J Am Acad Orthop Surg 2008;16(8):480–9.
[2] Balakrishnan A, Schemitsch EH, Pearce D, McKee MD. Distinguishing transient osteoporosis of the hip from avascular necrosis. Can J Surg 2003;46(3):187–92.
[3] Malizos KN, Zibis AH, Dailiana Z, Hantes M, Karachalios T, Karantanas AH. MR imaging findings in transient osteoporosis of the hip. Eur J Radiol 2004;50(3):238–44.
[4] Boutry N, Khalil C, Jaspart M, Vieillard M-H, Demondion X, Cotten A. Imaging of the hip in patients with rheumatic disorders. Eur J Radiol 2007;63(1):49–58.
[5] Navas A, Kassarjian A. Bone marrow changes in stress injuries. Semin Musculoskelet Radiol 2011;15(3):183–97.
[6] Krestan CR, Nemec U, Nemec S. Imaging of insufficiency fractures. Semin Musculoskelet Radiol 2011;15(3):198–207.
[7] Patel S. Primary bone marrow oedema syndromes. Rheumatol (United Kingdom) 2013;53(5):785–92.
[8] Korompilias AV, Karantanas AH, Lykissas MG, Beris AE. Bone marrow edema syndrome. Skelet Radiol 2009;38(5):425–36.
[9] Harvey EJ. Osteonecrosis and transient osteoporosis of the hip: diagnostic and treatment dilemmas. J Can Chir 2003;46:168–9.
[10] Yamamoto T, Kubo T, Hirasawa Y, Noguchi Y, Iwamoto Y, Sueishi K. A clinicopathologic study of transient osteoporosis of the hip. Skelet Radiol 1999;28(11):621–7.
[11] Curtiss Jr PH, Kincaid WE. Transitory demineralization of the hip in pregnancy: a report of three cases. J Bone J Surg Am 1959;41:1327–33.
[12] Shifrin LZ, Reis ND, Zinman H, Besser MI. Idiopathic transient osteoporosis of the hip. J Bone J Surg Br 1987;69(5):769–73.
[13] Uzun M, Ayhan E, Beksac B, Karaman O. Regional migratory osteoporosis and transient osteoporosis of the hip: are they all the same? Clin Rheumatol 2013;32(6):919–23.
[14] Xyda A, Mountanos I, Natsika M, Karantanas AH. Postpartum bilateral transient osteoporosis of the hip: MR imaging findings in three cases. Radiol Med 2008;113:689–94.
[15] Cahir JG, Toms AP. Regional migratory osteoporosis. Eur J Radiol 2008;67(1):2–10.
[16] Karantanas AH, Nikolakopoulos I, Korompilias AV, Apostolaki E, Skoulikaris N, Eracleous E. Regional migratory osteoporosis in the knee: MRI findings in 22 patients and review of the literature. Eur J Radiol 2008;67(1):34–41.
[17] Trevisan C, Ortolani S, Monteleone M, Marinoni EC. Regional migratory osteoporosis: a pathogenetic hypothesis based on three cases and a review of the literature. Clin Rheumatol 2002;21:418–25.
[18] Malizos KN, Karantanas AH, Varitimidis SE, Dailiana ZH, Bargiotas K, Maris T. Osteonecrosis of the femoral head: etiology, imaging and treatment. Eur J Radiol 2007;63(1):16–28.
[19] Vande Berg BC, Malghem JJ, Lecouvet FE, Jamart J, Maldague BE. Idiopathic bone marrow edema lesions of the femoral head: predictive value of MR imaging findings. Radiology 1999;212:527–35.